



ALGINATE

STOMA ADHESIVE

EVIDENCE BASED CASE STUDIES

BROUGHT TO YOU BY

OakMed[®] 
Giving you more choice.

www.oakmed.co.uk

Introduction

Case Studies

Healthy peristomal skin is an essential aspect in the quality of life as an ostomist and yet recent studies have highlighted that peristomal skin complications are significant (Herlufsen et al 2006, Williams et al 2010).

Literature has shown that of those people with stomas, approximately one third of colostomy patients and over two thirds of ileostomy and urostomy patients experience peristomal skin problems (Lyon et al 2000). The United Ostomy Association conducted a survey in 2000 and found that peristomal skin complications were the most common reason patients visited a Wound Ostomy Continence nursing service (Rolstad, Erwin- Toth 2004).

Contents

04 Case Study One

08 Case Study Two


10 Case Study Three

14 Case Study Four

16 Case Study Five

18 Summary

21 Products



One of the goals of good stoma management is to maintain healthy peristomal skin to the point where there should be no difference between the peristomal skin and the surrounding abdominal skin (Williams et al 2010). However the peristomal skin is extremely vulnerable and once damaged can be hard to treat, particularly with the problem of having to affix a skin barrier adhesive (Thompson et al 2011).

Alginates are quite abundant in nature although all commercial alginates are produced from marine brown algae (seaweed) (Woo-Ram 2007). Alginates made their first big impression in wound care in the 1980's as dressings for split skin donor sites. A study comparing the use of alginates and paraffin gauze on the donor sites had to be abandoned by Attwood (1989) as there was consistently better healing under the alginates (Heenan 2007).

It is not fully understood why alginate actively promotes healing. Alginates are biocompatible, hydrophilic (water loving) and biodegradable (Woo-Ram et al 2009). Once a gel has been formed via ion exchange between the alginate and the wound,

the wound secretions and bacterial contamination are minimised which promotes wound healing (Timmons 2009). It is also known that alginate dressings can exert bioactivity which may modulate cell function and thus influence the healing process (Thomas et al 2000).

The Alginate wafer (Oakmed Ltd, UK) has been designed to incorporate alginates in the ostomy bag wafer so that it can actively help with the healing of any sensitive, sore excoriated peristomal skin.

The following case studies are a great testament to the healing power of alginates and the improvement in patient quality of life and cost savings in resources and clinical time.

PATIENT HISTORY

The patient is a 78 year old female who was involved in a road traffic collision in mid 2010 from which she suffered abdominal injuries including a perforated small bowel and transverse colon. Both were repaired surgically, but the transverse colon became ischaemic and was subsequently resected with formation of an end colostomy in the right upper quadrant and mucous fistula in the left upper quadrant.

Observations on referral

The patient was initially in ICU and was referred to the Stoma Care Nurses (SCNs) for management of the stoma and mucous fistula. The patient was transferred to a surgical ward and initially recovered well, adapted to their stoma management, requiring minimal input from the SCN.

The patient became unwell with a wound infection and the wound eventually dehisced to leave a large open abdominal wound. After several days a loop of bowel was identified at the superior aspect of the wound preventing the use of VAC therapy. This subsequently developed into an enterocutaneous fistula and has since functioned as the stoma. Following this, the colostomy has remained minimally active.

Complications or problems being experienced

Initial complication was management of a large open abdominal wound incorporating a high output enterocutaneous fistula.

As the wound reduced and ultimately healed, the fistula remains and continues to function as a jejunostomy. Situated within an area of scar tissue, the enterocutaneous fistula is within a large skin dip, the surrounding skin is exceptionally uneven and fragile. This results in a 'para-stomal' area which is liable to 'breaking down', becoming sore and excoriated and is difficult to successfully adhere any products to the skin or to achieve a sufficient wear time.

Maximum wear time achieved was approximately 24 hours, the average was 6-12 hours. The outcome of this was that the patient became effectively housebound, suffered constantly from sore excoriated skin and became almost entirely dependent upon family and carers.

Community visits

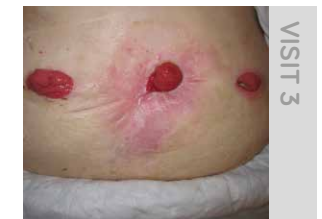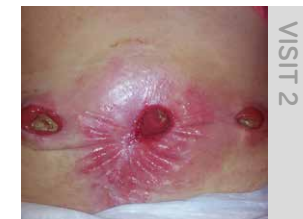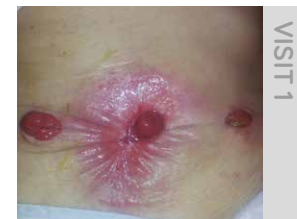The patient was seen on a daily basis by the SCNs as an in-patient and subsequently on a regular basis in the community. She continues to be seen every 2-3 weeks to assist with management of her stoma and fistula and to support her carers.

Treatment

A number of alternative products had been used, approximately 20 different types, from various manufacturers, all with hydrocolloid flanges. Most had been convex and all had been used with an adhesive seal, paste or a combination of both. I introduced the Oakmed Options Soft Convex Alginate bag, the SCA45-4120KV.

I re-visited the patient and found that she was continuing to use the product and reporting vastly improved reliability, comfort and wear time. The bag I initially applied lasted for 72 hours and subsequently for between 24 and 72 hours.

On review of the bag it was intact, the skin around her fistula was markedly improved than on any previous visit, displaying less discolouration and soreness. She is also able to leave the house for short periods, with family support for the first time in more than 12 months.



“It's marvellous”

Outcome

The patient continues to use the Oakmed SCA45-4120KV and remains very happy with it. She reports improved skin condition around the fistula and a wear time of up to 72 hours although she opts to change the bag every 24 hours, which naturally results in improved confidence and she is now beginning to return to a more normal lifestyle.

When visiting her at home, she now answers the door to me herself, and is able to participate in light household tasks and is regularly leaving the house for outpatients appointments as well as shopping. She is even attending family gatherings, an activity which she had considered unthinkable 3 months ago.

WHAT THE PATIENT SAID:

“I feel so much more confident in this bag, I can finally go shopping and visit my family”

“The bag is much more comfortable and reliable”

“My skin feels much less sore and I no longer live with the constant discomfort I did previously”



COST ANALYSIS over 1 week

Patient was changing bag on average every 12 hours (sometimes as often as 6 hourly)

Average convex product	£3.90 (per bag) x 14 (changes) =	£54.60
Average seal	£1.70 x 14 =	£23.80
Average paste	5p episode x 14 =	£0.70
	<u>Total =</u>	<u>£79.10</u>

Using Oakmed Alginate Soft Convex – Patient changing bag every 24 hours (could be 72 hours)

Convex bag	£4.35 x 7 =	£30.45
	<u>Total =</u>	<u>£30.45</u>

SAVING APPROXIMATELY £48.65 A WEEK

CONCLUSION

The patient has found that the Oakmed Options Soft Convex Alginate SCA45-4120KV ileostomy bag has been significantly more reliable than any other product trialled. It has shown appreciably improved wear time and comfort. The skin surrounding her fistula remains susceptible to damage from stomal effluent but the occurrence of this is greatly reduced and this has undoubtedly been due to the Oakmed Soft Convex Alginate bag.

PATIENT HISTORY

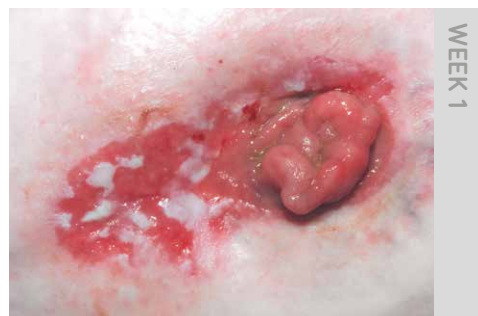This patient is 68 years old. She had surgery on her back in 1980 which affected her nervous system and left her incontinent. She has a loop colostomy.

The patient does not take any medication which may affect skin healing in any way. She is in good health otherwise.

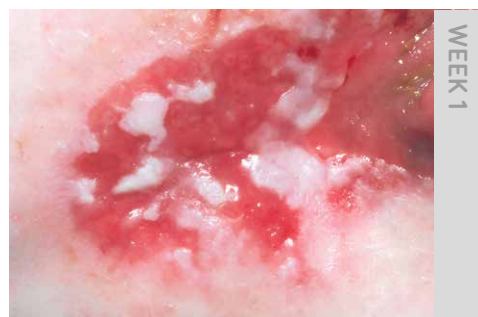
She has had sore skin for approximately one year. Problems with leakage made the skin ulcerate and become macerated and wet.

She has tried lots of different products, including various convex bags and different accessories in an effort to solve her skin problem, none of which really solved her issues.

She did have some success with an alginate based wound dressing which led us to think of the Oakmed Alginate bags for their skin healing and moisture absorption qualities.



WEEK 1



WEEK 1

Observations on referral

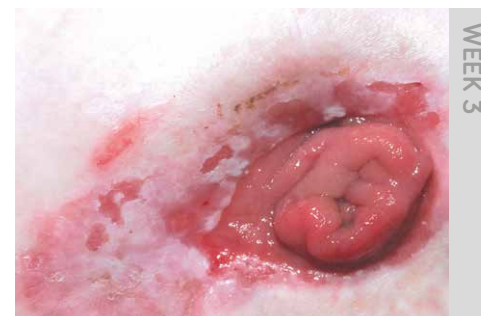On examination the patient's skin was raw and excoriated. Area of raw skin measuring 4cm by 2½cm, (see week 1).

The patient has a dip in the nine-o'clock position. This lady also complains of pancaking and is fearful of leaks which affects her mood.

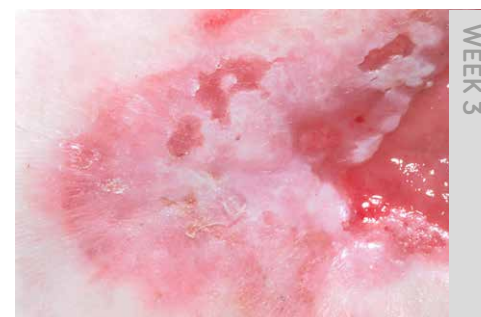Complications or problems being experienced

The patient complains of being sore and uncomfortable most of the time.

She was changing the bag four to five times a day because bags will not stick on to macerated skin and are therefore leaking.



WEEK 3



WEEK 3

The patient does still manage to go out and really tries not to let it stop her living her life.

The patient attends the Stoma Clinic regularly for her sore skin and leakage problems.

Treatment

We chose the Oakmed Alginate Connect 2 two piece bag AJH0015* (flange) with JH610 (closed bag). No accessories were used.

Outcome

After one week the area of macerated skin had decreased by 20-25%. After a further two weeks the area of macerated skin had decreased by 85% (see week 3).

*Product is now discounted, please speak to your Healthcare Professional for an alternative.

CONCLUSION

There is formation of granulation tissue, epithelialisation and contraction of the surface area of raw excoriated skin. The skin healing process was virtually complete after three weeks and was initiated in less than five days.



Macerated skin decreased by over 20% after just 7 days

After 21 days macerated skin had decreased by 85%

LEEDS TEACHING HOSPITAL

Two patients were assessed and agreed to take part in the Oakmed Alginate case study as per protocol.

The purpose of the study was to highlight the benefits of Alginate bags and how effective the alginate healing properties are, when used on sore, moist excoriated peri-stomal skin.

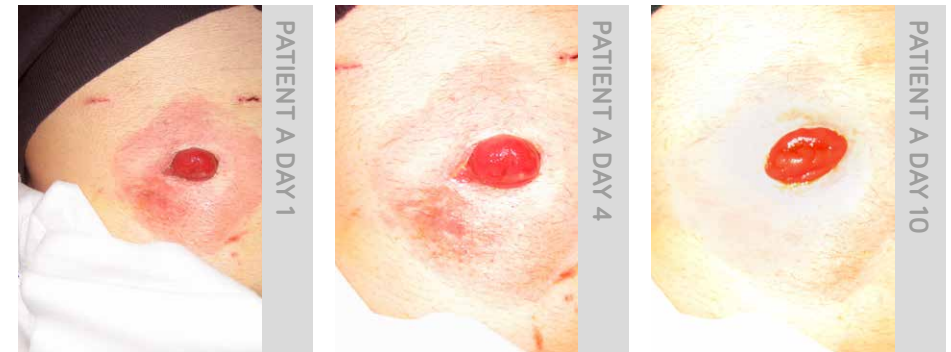It is also demonstrative of how cost effective Alginate bags are in terms of managing sore skin by eliminating the need for further product usage i.e. frequent appliance changes, use of skin protection barrier products, films, creams and wipes.

Each patient was individually assessed and was found to have peri-stomal excoriation due to irritant dermatitis. This inflammation of the skin is typically manifested by erythema, redness, burning and scaling of the skin. It may also lead to blistering. It is reported to be a non-specific response of the skin to direct chemical damage (Lyon C, Smith A, Griffiths C, 2000).

In this situation, the chemical damage was due to the corrosive nature of faecal liquid from leaking bags due to a flush recessed stoma. Peri-stomal skin problems create a unique challenge to stoma care nurses because certain topical ointments and creams can be very oily. Therefore the application of

these products affects the adhesion of any stoma bag unless the healing agent is integral with the bag, such as the alginate within Oakmed bags. Alginates are naturally occurring substances, used extensively in the wound care field and are proven to initiate skin healing and absorb moisture.

Decreased hospital stays require patients to have intensive education regarding peri-stomal issues, which can also be a challenge for the stoma care nurse and patient concerned. It could be argued that peri-stomal complications can be prevented with timely, optimal pre and post surgery skin care and the appropriate selection of a suitable bag.



PATIENT HISTORY, TREATMENT AND OUTCOME

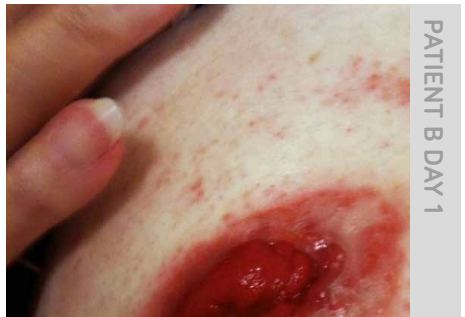Both case study participants underwent emergency surgery, which involved the removal of the whole of their large bowel (colon), and the formation of an ileostomy. Due to the acute nature of the surgery, both patients were not sited pre-operatively for stoma formation. This unfortunately resulted in inappropriately placed stomas by the surgeon and also stomas that became very flat and recessed at the abdominal surface. This caused frequent appliance leakages, resulting in sore peri-stomal skin.

On assessment the peri-stomal excoriation was evident due to the chemical damage of liquid faecal matter. Initial treatment by the ward nursing staff was skin barrier protection, hydrocolloid seals and flange retention strips. After two days the appliances continued to leak and a referral was made

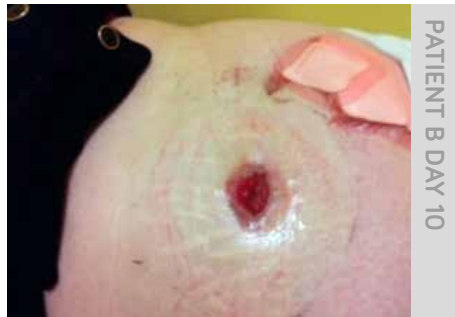to myself. I entered the individuals, after assessment, into the trial of Alginate bags and assessed their effectiveness.

The loss of peri-stomal skin integrity affects the persons entire well-being, confidence and quality of life. Sore skin leads to appliance leakages, pain, embarrassment and a complete interruption to their socioeconomic health. The cost of treating peri-stomal soreness is high.

The objective of this evaluation case study was to assess the effectiveness of Oakmed Alginate bags in the following categories, of which I have added a 7th dimensional assessment criteria. I felt this was significant on behalf of the participants (and reported by). In addition to the objectives set by Oakmed.



PATIENT B DAY 1



PATIENT B DAY 10

1. Nature of the peri-stomal skin at the commencement of the study
2. Evidence of healing of the peri-stomal skin
3. Reduction of the surface area of sore, excoriated peri-stomal skin
4. Reduction in pain and discomfort at bag changes
5. Evidence of absorption of moisture
6. Reduction in the need for accessories
7. Effect on the individual's mental, physical, psychological and emotional well-being/health

Both patients were then commenced on Oakmed Alginate Soft Convex drainable, SCA45-4120KV.

Following four days of the application of the Oakmed bag, dermatological improvement of the peri-stomal surface

was significant. By day 4, a complete resolution of pain, discomfort and leakages were apparent. Both patients had become depressed from not only the affects of acute surgery but the additional indignity of appliance leakage and sore, painful skin.

By day ten, both peri-stomal areas were completely healed. Both patients expressed their relief of no further episodes of discomfort, pain, soreness and embarrassment. A noticeable increase was observed in their general well-being, confidence and morale.

The additional benefits of cost reduction were also evident as we no longer required the use of ostomy belts, skin protection barrier films or flange retention strips. The patients appliance wear time also increased, with less bag changes: from five times per day to every three days.

OBSERVATIONS

“No pain or soreness after 10 days”

“Dermatological improvement of the peri-stomal surface was significant after 4 days”

“Wear time increased from 5 times per day to every 3 days after 10 days”



PATIENT HISTORY

This patient is a 24 year old male who had a panproctocolectomy in 2009 for Crohn's disease. At this present time the patient is not taking any medications and agrees to take part in this case study. He was using a Hydrocolloid one piece appliance but in his words had tried "everything". He had in fact tried about five different types of bag but his skin had been sore for months. He had a dermatological referral and had been re-educated to correct the method of his stoma management as he had flitted from one product to another and had also tried many types of accessories.

Observations on referral

This patient was self-referred for advice. On inspection the ileostomy appeared slightly proud to the skin, sloughy and slight ulceration was noted on aperture. The peri-stomal skin appeared excoriated and red with some bleeding points noted.

His stoma had been situated high at his own request and he reported constant leakage which was causing his skin excoriation. He had no pancaking or template problems but reported that his skin was incredibly itchy and as a result he had been suffering from a lack of sleep and so had become very tired.

When asked to score his pain from one to ten (ten being the worst) he said ten on occasions and seven at other times.

He was often in the stoma clinic with his problems, at least once a week for a twenty minute appointment. He preferred this to community visits.

Treatment

He was advised by the Clinical Nurse Specialist to use a bag from the Oakmed range of Alginate bags with their skin healing and moisture absorption properties.

The range includes one piece flat, closed and drainable bags, two piece flat bags and soft convex drainable bags.

The product chosen was AV-4120k (flat flange drainable bag).

No skin creams or barrier films were used as this is not necessary with the Alginate products as all the skin healing is within the flange itself. He was also educated not to use inappropriate wipes on his skin and to change the bag daily.

Improvements

The patient was seen on day five to repeat the photographs. The peri-stomal skin appeared less excoriated and not as red. The patient reported less itching and no leakage. Evidence is seen on the photographs of a marked reduction of surface area of sore peri-stomal skin and evidence of a reduction in the amount of moisture present.

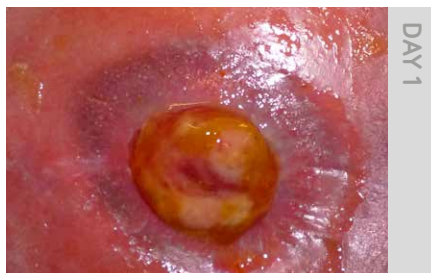Outcome

The patient reported how pleased he is with his new product and how well his peri-stomal skin is responding. He now attends clinic less and for a reduced time, his visits are down to ten minutes maximum.

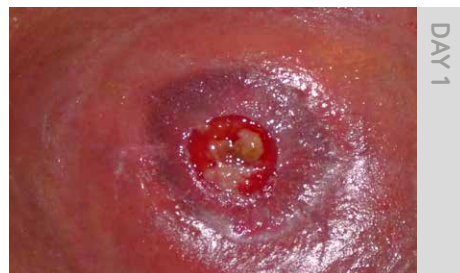He reports his quality of life is much improved and his pain score from one to ten (ten being the worst) has reduced to four. He also reports that his sleep pattern is much improved and he is less tired. He has booked a summer holiday.

CONCLUSION

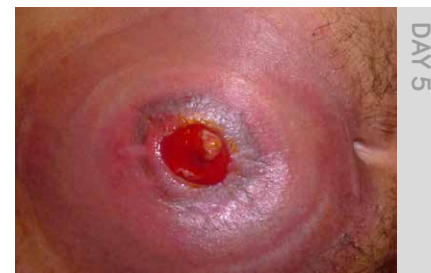The patient's skin had visibly improved within just 5 days and was well on its way to being completely healed. The patient reported that his pain score (1-10, ten being the worst) had reduced from 7-10 to 4.



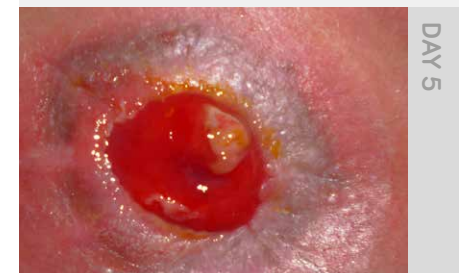DAY 1



DAY 1



DAY 5

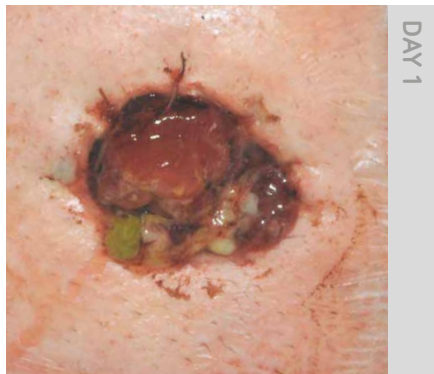


DAY 5

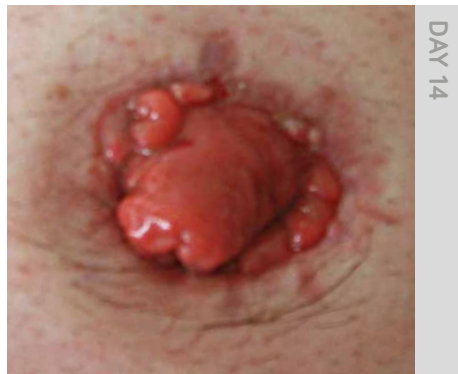PATIENT HISTORY

This patient, aged 42, was admitted for ileo-anal bag surgery. He already had an ileostomy following sub-total colectomy for ulcerative colitis.

Not on any medication which would affect skin healing properties.
No known allergies.



DAY 1



DAY 14

Observations on referral

On admission a bright red adhesive shaped erythema was noted, excoriated in places, showing sensitivity to his current adhesive.

The patient said it had been like this for a while and he had started to have problems with the bag adhering to his

skin which in turn led to an increased number of bag changes.

The area was described as, 'not painful but uncomfortable.'

There were no obvious signs of leakage or any other reason for sore skin i.e. template size, dips or creases in the skin, position of the stoma.

Complications or problems being experienced

The patient said his skin had been like this for a while getting gradually worse and was causing him discomfort, his bags weren't sticking properly.

Treatment

We chose Oakmed Alginate drainable flat bag AV-4120k as product of choice because of the skin healing properties of the alginate within the adhesive.

We have used this Alginate product in our department previously on problem skin and had some excellent results.

This bag was applied immediately after surgery and initially was left in-situ but was changed every other day at a later post-op stage.

No accessories were used with the product.

Improvements

No leaks were experienced with the Alginate product.

The patient said "it felt a lot more comfortable within a couple of days".

The area of erythema reduced in size after one week. The skin was dull red rather than inflamed.

Outcome

After a period of two weeks there was no residual inflammation left. Some patchy red areas within the excoriated area were returning to normal.

The patient continues to use the Alginate drainable bag successfully rather than his previous appliance, changing the bag on alternate days.

CONCLUSION

The patient's skin was healed successfully within a 14 day period.

No accessories were needed in addition to the Alginate bags.

The cost was for the bags only.

The patient remains happy with his bag.

It felt a lot more comfortable within a couple of days



Executive Summary

Case Studies

Skin problems are common among patients with a stoma. Patients may develop a skin problem for a variety of reasons, many of which are beyond their control. This can result in a real reduction in quality of life as patients feel that they are not in control.

The main outcomes assessed in these case studies were resolution of sore peristomal skin, patient quality of life, reduction in amount of product and accessories required to solve the peristomal skin problem and reduction in time required with the Stoma Care Nurse Specialist.

In this cohort the patients all found their quality of life had improved as the leaks were resolved and sore peristomal skin was healed. There was no need for any accessories while using the Alginate products whereas a number had been used previously. The number of bag changes also dramatically reduced. This represented a significant cost saving in each case.



The sore peristomal skin, which had been a problem for many months for a couple of patients, was showing signs of healing within a few days, and was healed for three of the patients by day 10. The fourth patient had seen 85% healing in her wound. The patient who had the fistula, which had formed a jejunostomy found her skin improved within a few days but full wound healing was reached at 4 months. The output of the jejunostomy was managed well with this bag.

The resolution of these problems while using the Alginate product resulted in the reduction of the amount of clinic time required from the Stoma Care Nurses with these patients.

The Oakmed Alginate product was successful in its outcomes of increasing patient quality of life, reducing the need for extra products and accessories, initiating wound healing and reducing the amount of time required by the Stoma Care Nurses.

Further in depth study would be required to test conclusively how effective the Alginate product is compared to others in the arena of wound healing but the Oakmed Alginate products may represent a significant cost effective treatment of sore peristomal skin.

Want to know more about Alginates?
Visit www.oakmed.co.uk/alginate

Acknowledgements

Thank you to all those patients and healthcare professionals who have been involved.

David Greenwood, Stoma Care Nurse Specialist, Macclesfield District General

Sarah Taylor, Stoma Nurse Specialist, University of Coventry and Warwickshire Hospital

Julie Hemingway, Nurse Specialist Manager, Colorectal Nursing Team, St James University Hospital, Leeds

Jane Gascoigne, Colorectal/Stoma Care Nurse Specialist, The Alexandra Hospital, Redditch

Lesley Verrill and Gillian Powell, Stoma Care Clinical Nurse Specialists, York Teaching Hospital, NHS Foundation Trust

Oakmed are constantly seeking to improve patient's lives by developing technically advanced products. This ongoing process of product evaluation and development includes validation of the efficiency and effectiveness of our products. If you would like to be part of the development process please contact your Territory Manager.



PRODUCTS

Flat Alginat bags

With **15% Alginat**, stimulates healing for sore skin.

Drainable Midi Alginat

AV-4320K Window, filter, soft cover both sides, soft touch closure.

Pack Size: 30

Hole Size	Window
Cut to fit 20 to 60mm	AV-4320K

Closed Mini Alginat

AHP11C10 Window, opaque, filter, soft cover both sides.

Pack Size: 30

Hole Size	Window
Cut to fit 10 to 50mm	AHP11C10

Drainable Standard Alginat

AV-4120K - AV-4160K Window, filter, soft cover both sides, soft touch closure.

Pack Size: 30

Hole Size	Window
Cut to fit 20 to 60mm	AV-4120K
Pre-cut to 25mm	AV-4125K
Pre-cut to 30mm	AV-4130K
Pre-cut to 35mm	AV-4135K
Pre-cut to 40mm	AV-4140K
Pre-cut to 45mm	AV-4145K
Pre-cut to 50mm	AV-4150K
Pre-cut to 55mm	AV-4155K
Pre-cut to 60mm	AV-4160K

Closed Standard Alginat

AHP5C20 - AHP5C60 Window, opaque, filter, soft cover both sides.

Pack Size: 30

Hole Size	Window
Cut to fit 20 to 60mm	AHP5C20
Pre-cut to 25mm	AHP5C25
Pre-cut to 30mm	AHP5C30
Pre-cut to 35mm	AHP5C35
Pre-cut to 40mm	AHP5C40
Pre-cut to 45mm	AHP5C45
Pre-cut to 50mm	AHP5C50
Pre-cut to 55mm	AHP5C55
Pre-cut to 60mm	AHP5C60

Closed Maxi Alginat

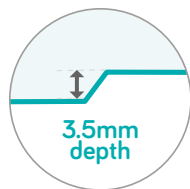
AHP8C20 Window, opaque, filter, soft cover both sides.

AHP7C20C Clear, soft cover one side.

Pack Size: 30

Hole Size	Window	Clear
Cut to fit 20 to 90mm	AHP8C20	AHP7C20C

Offering superior flexibility and comfortable wear as our Soft Convex range, our Low Profile Soft Convex range gives you 3.5mm of convexity.



Closed Standard Alginate Low Profile Soft Convex

LPSCA28-0420K - LPSCA47-0445K Window, opaque, filter, soft cover both sides.

Pack Size: 20

Hole Size	Plateau Size	Window
Cut to fit 20 to 28mm	28mm	LPSCA28-0420K
Pre-cut to 25mm	28mm	LPSCA28-0425K
Cut to fit 20 to 40mm	40mm	LPSCA40-0420K
Pre-cut to 30mm	40mm	LPSCA40-0430K
Pre-cut to 35mm	40mm	LPSCA40-0435K
Cut to fit 20 to 47mm	47mm	LPSCA47-0420K
Pre-cut to 40mm	47mm	LPSCA47-0440K
Pre-cut to 45mm	47mm	LPSCA47-0445K

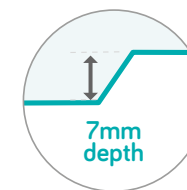
Drainable Standard Alginate Low Profile Soft Convex

LPSCA28-4115KV - LPSCA47-4145KV Window, opaque, filter, soft cover both sides, soft touch closure.

Pack Size: 20

Hole Size	Plateau Size	Window
Cut to fit 15 to 28mm	28mm	LPSCA28-4115KV
Pre-cut to 20mm	28mm	LPSCA28-4120KV
Pre-cut to 25mm	28mm	LPSCA28-4125KV
Cut to fit 15 to 40mm	40mm	LPSCA40-4115KV
Pre-cut to 30mm	40mm	LPSCA40-4130KV
Pre-cut to 35mm	40mm	LPSCA40-4135KV
Cut to fit 15 to 47mm	47mm	LPSCA47-4115KV
Pre-cut to 40mm	47mm	LPSCA47-4140KV
Pre-cut to 45mm	47mm	LPSCA47-4145KV

Naturally the flexible choice for maximum security and added confidence, our Soft Convex range offers 7mm of convexity to fit the contours of your body for more comfortable wear.



Closed Standard Alginate Soft Convex

SCA25-0420K - SCA45-0440K Window, opaque filter, soft cover both sides.

Pack Size: 20

Hole Size	Plateau Size	Window
Cut to fit 20 to 24mm	25mm	SCA25-0420K
Cut to fit 20 to 34mm	35mm	SCA35-0420K
Pre-cut to 25mm	35mm	SCA35-0425K
Pre-cut to 30mm	35mm	SCA35-0430K
Cut to fit 20 to 44mm	45mm	SCA45-0420K
Pre-cut to 35mm	45mm	SCA45-0435K
Pre-cut to 40mm	45mm	SCA45-0440K

Drainable Standard Alginate Soft Convex

SCA25-4120KV - SCA45-4140KV Window, opaque, filter, soft cover both sides, soft touch closure.

Pack Size: 20

Hole Size	Plateau Size	Window
Cut to fit 20 to 24mm	25mm	SCA25-4120KV
Cut to fit 20 to 34mm	35mm	SCA35-4120KV
Pre-cut to 25mm	35mm	SCA35-4125KV
Pre-cut to 30mm	35mm	SCA35-4130KV
Cut to fit 20 to 44mm	45mm	SCA45-4120KV
Pre-cut to 35mm	45mm	SCA45-4135KV
Pre-cut to 40mm	45mm	SCA45-4140KV

BROUGHT TO YOU BY



www.oakmed.co.uk

Oakmed Limited,
Unit B, The I O Centre,
Barn Way, Lodge Farm Industrial Estate,
Northampton, NN5 7UW
Freephone: 0800 592 786
Main: 01604 586 529 | Fax: 01604 584 784



Stay connected
Like us on facebook @OakmedUK

